



Animal Medical Clinic

J.S. GODWIN D.V.M.
S.M. JOINER D.V.M.
M.J. THOMSON D.V.M., Ph.D.
R.E. YOUNG D.V.M.
S.W. CARRAWAY D.V.M.
M.N. CRAIG D.V.M.
C.W. RODRIGUEZ D.V.M.

Animal Medical Clinic, P.A.
4020 South Babcock Street
Melbourne, FL 32907
phone (321) 727-2421
fax (321) 722-2694

www.animal-medical-clinic.com

June 5, 2009

Brevard County Animal Control
Attn. Denise Karlton
5100 West Eau Gallie Blvd.
Melbourne FL 32935

Ms. Karlton,

As per your request, I am writing this letter to clarify the findings of my physical exam of "Molly May", a 6 month old, female, Labrador mix owned by David Vanschaick performed on 5/26/2009. The dog on presentation had severe, generalized papular eruption with alopecia. The entire face was affected, including the eyelids. There was severe erythema of the skin as well. The remainder of the physical exam was normal. Skin scrapings were performed which revealed a significant number of demodex canis mites encompassing all life stages. Skin cytology showed a mild pyoderma. The heartworm test performed was negative.

A diagnosis of generalized demodicosis with secondary pyoderma was given to "Molly May". Her DAPP and Rabies vaccinations were given and Simplicef (an antibiotic) was prescribed. In addition, I discussed with the owner the treatment options for "Molly May" including Mitaban dips, milbemycin therapy, and ivermectin therapy. He informed me that he could not afford the Mitaban dips or the melbemycin, so I prescribed ivermectin. However, to date, he has still not picked up the ivermectin to begin treatment. I also requested a recheck of "Molly May" in 4 weeks to recheck her condition.

I hope this clarifies the medical record. Please let me know if I can be of further assistance.

Sincerely,

Michael J. Thomson D.V.M., Ph.D.

Denise Kariton
Brevard County Animal Services
Phone:

Acc: 2075

Animal Emergency & Critical Care Center of Brevard
2281 W. Eau Gallie Boulevard
Melbourne, Florida 32935
321-725-5365 ~ FAX 321-242-5755

Patient: 2731 PARK LN 122309
Species: CN
Breed: Labrador Ret Mix
Color: Black

Sex: FE
DoB:

Date: 12-23-09

Time: _____ am/pm

Brevard County Animal Services Patient Information

Officer Name: Kariton #44 ID#: A09-025389

Location Found/ Picked-Up: 2731 Park Ln. NEPB

Known Owner: David Vanschick "Molly Mae"

Contact Number: (____) _____ Cell Phone: (____) _____

PRIMARY REASON FOR VISIT: Skin Condition - Cruelty Investigation

Dog Cat Other _____

Sex: M F

Neutered: Yes No

Breed: LAB

Color: BLK

Temperature: 104.0 Pulse: 170 Respirations: 40 Weight: 59.2 lbs

Physical Exam Findings: severe deep pyoderma, large fleas
allopecia, generalized; deep ulcers & excoriations, lick granuloma

DDX: Pyoderma, Flea Allergy, severe deep purulent dermatitis

TX: Skin scraping; demodex pos! Byprnex 0.03mg/kg SA 1.3ml
Baytril 5mg/kg SA 2mg/kg

rec. Cepstar rec Advantage rec. Ceph 500 1 BID per 1 month

sudicated bath in 1-2 days w/ Malasse's Shampoo

treatment for demodex mange

Severe neglect, animal is very **Authorization** uncomfortable, painful & suffering

I hereby authorize the veterinarian to examine, prescribe for, or treat the above described pet. Brevard County Animal Services and Enforcement assumes responsibility for all charges incurred in the care of this animal.

Signature of responsible officer: Denise Kariton #44

December 30, 2009

Dr. Asher
South Animal Care Center
5100 W. Eau Gallie Boulevard
Melbourne FL 32934
Fax: (321)253-6623

Dear Dr. Asher,

This letter is in reference to 2731 Park Ln 122309, the female, 9 months old Labrador Ret Mix "Molly Mae" owned by # 44 Denise Karlton. 2731 Park Ln 122309 was presented on December 24, 2009, for Severe Skin Problems.

HISTORY:

Molly Mae was taken from owner for neglect of care

PHYSICAL EXAMINATION:

TEMP 104.0, RR 40, HR 120, MM/CRT pink < 2 sec, PULSE normal.

Gen.Attitude/Cond.: restless, painful, kept circling, trying to rub his skin, thin

Integument: generalized severe deep pyoderma, alopecia, lichenification, bad odor, deep ulcers from self mutilation, severe pruritus, large fleas

DIAGNOSIS/DIFFERENTIALS:

Possible differentials include: Demodicosis, Pyoderma, Dermatitis, and Flea Allergy.

DIAGNOSTICS PERFORMED AND INTERPRETATION:

12/24/2009 Skin Scraping Qty: 1.00 (Done) Verena A. Faure, DVM
large bacteria, yeast and demodex mites

12/24/2009 Baytril 22.7 mg/ml Inj Qty: 1.00 (Done) Verena A. Faure, DVM
@ 5 mg/kg SQ

12/24/2009 Buprenorphine Inj/CC Qty: 1.00 (Done) Verena A. Faure, DVM
@ 0.03 mg/kg im (to relieve pain and discomfort)


12/24/2009 Benadryl Inj/CC Qty: 1.00 (Done) Verena A. Faure, DVM
@ 1 mg/kg SQ

COMMENTS:

We recommended Treatment for Demodicosis at the shelter, Capstar and Advantage for fleas, Cephalexin 500 mg TID, and medicated baths with Malaseb or a similar shampoo.

The black Labrador Mix was in very poor condition, she was restless and extremely itchy, most of her hair coat was rubbed off or her hair had fallen out due to prolonged skin disease.
Her prognosis is fair under good care.

Sincerely,




Verena A. Faure, DVM
Animal Emergency and Critical Care Center of Brevard
2281 W. Eau Gallie Blvd.
Melbourne, FL 32935
(321) 725-5365



BREVARD COUNTY
BOARD OF COUNTY COMMISSIONERS

**INTER-OFFICE
MEMORANDUM**

To: Robert Brown, Captain
Animal Services and Enforcement (BASE)

From: Robbie Asher, DVM 
South Animal Care and Adoption Center (SACC)

Subject: "Molly" Black Labrador, Animal ID #477242

Date: January 7, 2010

A female black Labrador retriever ID #477242 was brought into the South Animal Care Center (SACC) on 12/23/09 on cruelty investigation hold. The dog was initially taken to the Animal Emergency & Critical Care Center of Brevard. Findings included, severe deep pyoderma, generalized alopecia, severe flea infestation, and confirmed demodectic mange on skin scraping. Treatment recommendations included antibiotics for the severe pyoderma, medicated baths, and treatment for demodex and fleas.

The treatment protocol for this dog consists of treatment with Promeris, a topical medication, labeled for use for both fleas and demodectic mange. This treatment will be given every two weeks for a minimum of 2-3 months or until a negative skin scraping is obtained twice on biweekly skin scrapings. Medicated baths will also be given every 2 weeks 24-48 hours prior to the topical medication. Cephalexin 500mg, an antibiotic, will be given for one month to treat the severe skin infection.

Upon arrival to SACC on 12/23/09, the dog was "very uncomfortable, painful and suffering" as stated by the emergency's clinic attending veterinarian. Reassessment today 1/7/10, two weeks after initial exam, revealed a great improvement in overall condition of the animal. The pyoderma has greatly improved and there are no longer red draining sores. Prognosis for recovering is good with proper treatment. Signs observed during examination indicate that this has been a chronic condition. Continued preventatives and continued treatment may be necessary for the rest of this pet's life.





J.S. GODWIN D.V.M.
S.M. JOINER D.V.M.
M.J. THOMSON D.V.M., Ph.D.
R.E. YOUNG D.V.M.
S.W. CARRAWAY D.V.M.
M.N. CRAIG D.V.M.
C.W. RODRIGUEZ D.V.M.

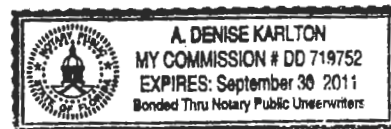
Animal Medical Clinic, P.A.
4020 South Babcock Street
Melbourne, FL 32901
phone (321) 727-2421
fax (321) 722-2694

www.animal-medical-clinic.com

January 7, 2010

I certify that since Dr. Thomson's letter of June 5, 2009, Mr. David Vanschaick has not returned to Animal Medical Clinic for any exams, treatments or medications for his dog, Molly May.

Jeffrey S. Godwin, DVM



A. Denise Karlton
1-7-2010

